

# Evaluation of the protective role of the aqueous extract of *Agrimonia eupatoria* L. against hepatotoxicity and histological and biochemical changes in adult male rats treated with orlistat

**Hawraa Jasim Mohamed Ali, Rasha Abdul Ameer Jawad**

University of Kerbala / Department of Biology, College of Education for Pure Sciences, Kerbala, Iraq.

Corresponding author: [hawraa.j@s.uokerbala.edu.iq](mailto:hawraa.j@s.uokerbala.edu.iq)

**Received: 26/4/2025**

**Accepted: 25/5/2025**

**Published: 15/6/2025**

**Abstract** - The study aimed to analyze the impact of the aqueous extract of Agrimony (AE) (*Agrimonia eupatoria* L.) on the hepatotoxic outcomes induced with the aid of orlistat (ORL) in grownup male albino rats on few physiological parameters. The study was performed on 20 male albino rats, which had been randomly divided into four groups, with 5 animals per group. Their ages ranged between three and four months, and their weights ranged between 275-375 grams. The experiment lasted for 30 days, as follows:

The first institution (G1) changed into given 1 ml of distilled water (DW) each day and served as the control group (negative). The second institution (G2) was given orlistat (ORL) (32 mg/kg) and served as the control group (positive). The third group (G3) was given aqueous extract of agrimony (AE) at a dose of four hundred mg/kg. The fourth institution (G4) turned into given the agrimony extract (AE) (four hundred mg/kg) first, accompanied three hours later by a dose of orlistat (ORL) (32 mg/kg) and served as the preventive organization.

**Results:** The results confirmed a great increase ( $P \leq 0.05$ ) in the stages of liver enzymes AST, ALT, and ALP, and a large decrease ( $P \leq 0.05$ ) in the concentrations of general protein, albumin, and globulin within the advantageous control (G2) in comparison to the manage organization (G1). However, the effects additionally indicated a widespread decrease ( $P \leq 0.05$ ) in liver enzymes in the G3 and G4 agencies compared to the G2 group, and a significant boom ( $P \leq 0.05$ ) in the 3 proteins in comparison to the G2 institution.

**Conclusion:** We conclude from the above that the use of Agrimony herb (AE) may also have protective potential against the consequences of acute hepatotoxicity resulting from the drug Orlistat and can enhance physiological and

histological changes, as the histological sections showed a significant improvement in the liver tissue and were close to the sections of the negative control group.

**Keywords** - Orlistat, *Agrimonia eupatoria* L., Liver Damage, Medicinal Plants, Ghafis.

## INTRODUCTION

Medicinal plant life is a repository of phytochemicals as a vital supply of antioxidants in traditional medicine. Many medicinal plants have been used to deal with diseases due to their antioxidant content material, which is characterized by means of their high ability to scavenge reactive oxygen species (1). Given the effectiveness of herbal drug treatments, there has been an increasing number of critical healing positions (2). The use of medicinal plant life has witnessed a tremendous growth globally, with about 25% of modern-day healing drugs generally derived from medicinal flora (3). The use of medicinal flora in the prevention and treatment of many diseases is due to their effectiveness, clean availability, low price, and absence of side effects (4). A wide variety of medicinal plants can defend the body from the toxic results of medicine and chemical substances. They additionally have extensive physiological outcomes through their shielding function towards oxidative damage and the prevention and protection against diseases as a consequence of oxidative stress (5). Polyphenols are the maximum common secondary metabolites in plants and can interact with enzymes and other organic molecules based on their shape, molecular weight, and hydroxyl groups (6). Technology and expertise of plant chemical composition are assisting in improving the usage of plant-derived phytochemicals (7).

*Agrimonia eupatoria* L., normally referred to as Ghafis, performs a critical role in conventional herbal remedy (8). It is a perennial herb belonging to the Rosaceae family and consists of approximately 20 species according to the list of medicinal flora (9). *Agrimonia eupatoria* (AE) is an important source of bioactive compounds with therapeutic potential (10). Chemical evaluation of agrimony indicated that it incorporates a wide range of bioactive compounds, inclusive of tannins, flavonoids, phenolic acids, terpenoids, and unstable oils (11). A observe indicated the presence of 34 phenolic compounds in agrimony using mass spectrometry (12). It additionally includes polysaccharides, catechin, procyanidin, coumarin, silica, malic acid, phytosterols, iron, in addition to nutrients B and K (13). Agrimony consists of sixty-eight terpenoids, seventy-three phenolic compounds, and flavonoids (14). Fifty-two unstable components were observed inside the leaves and roots of agrimony (15). Agrimony also contains nitrogenous compounds: choline, nicotinic acid, nicotinamide, hydroxycinnamic acids (caffeine, chlorogenic), terpenoids, coumarins, steroids, and saponins (16), carbohydrates (glucose, fructose, sucrose, galactose, arabinose, rhamnose, xylose, ribose), and organic acids (citric, malic, oxalic, tartaric (10), in addition to paracoumaric and benzoic acids (17). Chlorogenic acid, hesperidin, morin, quercetin, rutin, and sinapic acid (18). Agrimony has huge medicinal importance in folk medicinal drugs as it has been used to deal with liver and gallbladder diseases, lung diseases, weight problems, and diabetes (19), bladder swelling, as an astringent, and to treat pores and skin injuries. It aids in wound recovery and eye infections (20). It is a sedative, stomach tonic, blood cleanser, diuretic, menstrual stimulant, and anti-inflammatory. It has been used to deal with hepatitis, splenitis, ulcers, jaundice, and gastrointestinal problems (8). It is also used to deal with colds, bleeding, and tuberculosis. It is a cholagogue, antihemorrhagic, antibacterial, and antifungal agent (14). It is known for its antimicrobial, antioxidant, neuroprotective, and hepatoprotective results (11). It also has antiviral (21), antitumor, anti-pain, and neuroprotective properties, which include the treatment of pyelonephritis and inflammatory oral mucosal diseases (10). A observe indicated that agrimony possesses anti-inflammatory and hepatoprotective properties (22). A previous study showed that the plant includes high levels of phenolic acids, flavonoids, and phenyl succinate, which may additionally give an explanation for its antioxidant activity (23).

Orlistat is one of the most broadly used weight reduction medicines and the best non-prescription weight reduction remedy approved by the FDA and the European Medicines Agency (24). It is offered under the brand name Xenical and is a clearly happening, saturated hydrogenated by-product of

lipstatin called tetrahydrolipstatin (25). It is a molecule derived from *Streptomyces oxytricini* and works through inhibiting the activity of pancreatic and gastric lipases. Orlistat works by inhibiting lipases in the stomach and pancreas, as it can bind to lipases within the digestive tract (26). Orlistat inhibits the absorption of approximately 30% of dietary fat, reducing the amount of fat absorbed and its excretion in the feces (27). Triglycerides are not hydrolyzed into free fatty acids that are readily absorbable in the intestine, and only small amounts are absorbed systemically (28). The most common gastrointestinal side effects of orlistat are dyspepsia, diarrhea, flatulence, and upset stomach (29). Other side effects include steatorrhea, loose, oily stools, increased fecal incontinence, rectal bleeding, bloody stools, sigmoid colitis, diverticulitis, and muscle cramps (30). Due to orlistat's inhibition of the major detoxification enzyme carboxylesterase-2, it increases the risk of liver, pancreatic, and kidney damage (31). Orlistat use has been associated with several mild to moderate gastrointestinal side effects, as well as nephrotoxicity and hepatotoxicity (32). A previous study reported the potential for hepatotoxicity and nephrotoxicity associated with orlistat administration (33). The drug caused a direct deleterious effect on liver tissue (34). A previous study demonstrated that orlistat caused significant and severe liver, kidney, and cerebellar damage in rats treated at a concentration of 32 mg/kg body weight (35). The purpose of the current study was to evaluate the protective efficacy of the aqueous extract of Agrimony (AE) against orlistat-induced hepatotoxicity (ORL) in male rats.

## **MATERIALS AND METHOD EXPERIMENTAL ANIMALS:**

Our current study was conducted in the Animal House of the College of Pharmacy/University of Karbala, the College of Education for Pure Sciences/University of Karbala, and private laboratories to conduct the necessary tests. This was conducted over 30 days, from October to November 2024. (20) adult male albino rats (Wister) were used in this study, weighing 275-375 grams and aged 3-4 months (15-17 weeks). The animals were distributed in special plastic cages measuring (15 x 40 x 25) cm, equipped with metal lids and equipped with special water drinking bottles with a capacity of 500 ml and a metal nipple at the end. The floor was covered with fine sawdust. The cages were kept clean, replaced twice a week, and continuously sterilized with disinfectants. The watering bottles and the animal housing room were also kept clean. All animals were subjected to standard laboratory conditions, including a temperature of 20-25 degrees Celsius, a light cycle of 12

hours of light and 12 hours of darkness, and adequate ventilation. The animals were provided with water and standard feed ad libitum throughout the study period.

#### **Preparation of the aqueous extract of *Agrimonia eupatoria* L:**

The agrimony plant was obtained from the Attari Bozorg Zarafat Company in Isfahan, Iran. The aerial parts of the plant were thoroughly cleaned of impurities and ground manually to obtain small pieces. The powder was then ground using an electric grinder to obtain a very fine powder, which was stored in glass containers until use in the extraction process. (50) grams of the dry fine powder prepared from the agrimony plant was soaked in (500) ml of distilled water in a glass flask. The mixture was then left for 24 hours at room temperature, stirring occasionally. After a full day, the mixture was filtered using several layers of medical gauze to remove suspended particles. The extract was then filtered using filter paper to obtain a clear solution. The filtrate was then placed in clean, sterile glass dishes and left in a room under a draft to obtain the dry extract. It was then placed in glass bottles and stored in the refrigerator until use. The required weights for the experiment were prepared: 400 mg/kg of body weight after dissolving it in distilled water, according to the weights of the experimental animals using the experimental tool (36).

#### **Orlistat Dose Preparation:**

Orlistat was obtained in capsule form at a dose of 120 mg/kg of the active ingredient (the dose used in humans) from pharmacies in the holy Karbala Governorate. The dose was prepared at the concentration required for the current study, which was 32 mg/kg of body weight, once daily. The animals were dosed with 0.75 ml of the solution after dissolving it in 2.5 ml of distilled water for each concentration using a dosing device. Each capsule was dissolved in 10 ml of distilled water, and 0.75 ml of the prepared solution was withdrawn and administered to the animal. This amount is equivalent to 0.025 ml per 10 g of body weight (35).

#### **Experimental Design:**

This experiment was designed to determine the protective effect of the aqueous extract of the plant *Agrimonia eupatoria* L. on some physiological parameters in male albino rats treated with the drug Orlistat at a concentration of 32 mg/kg once daily for one month. The study was conducted in both the College of Education for Pure Sciences/Department of Life Sciences and the College of Pharmacy/University of Karbala, as well as private laboratories for conducting tests. The study was applied

to 20 male rats, which were divided into four random groups, with five adult male albino rats per group, as follows:

- Group One (G1): This group represented the control group. Negative, given 1 ml of distilled water (DW) daily for 30 days.
- Group Two (G2): This group represented the positive control. The animals were administered daily with the drug Orlistat orally at a concentration of 32 mg/kg (with each 32 mg of the drug dissolved in 2.5 ml of distilled water). Each animal received 0.75 ml of the prepared solution once daily for 30 days. (37).
- Group Three (G3): This represented the plant group. The animals in this group consumed a cold aqueous extract prepared from the aerial parts of the *Agrimonia eupatoria* L. plant at a concentration of 400 mg/kg body weight daily for 30 days. (38)
- Group Four (G4): This represented the preventive group (AE+ORL). The animals were dosed daily with an aqueous extract of *Agrimonia eupatoria* L. at a concentration of 400 mg/kg, and 3 hours later, they were dosed with Orlistat at a concentration of 32 mg/kg of body weight daily for 30 days. (37,38)

#### **Blood Sample Collection:**

After 30 days from the start of the experiment, the animals were anesthetized with xylazine and ketamine injections. The animals were then removed from their cages, and blood was drawn directly from the heart-by-heart puncture to obtain the largest possible amount of blood using 5 ml medical syringes. The blood samples were placed directly into sterile, 10 ml gel tubes, free of anticoagulant, and left at laboratory temperature for 15-20 minutes. The tubes were then placed in a centrifuge, which was operated at 3,000 rpm for 10 minutes to obtain serum. The serum was transferred to dry, clean, sterile, and labeled tubes. The sera were then stored in Eppendorf tubes. All of these tubes were stored at -4°C until analyzed for the following parameters:

- (AST, ALT) level measurement (39).
- (ALP) level measurement (40).
- Total protein measurement (41).
- Albumin protein measurement (42).
- Globulin protein measurement (43).

#### **Histological Study**

After blood samples were collected from the animals, they were immediately dissected by making an incision in the abdominal cavity from the bottom upwards towards the heart, reaching the sternum. The liver was excised after removing the fatty tissue attached to it. The liver was then washed with water to remove the blood. The liver was cut lengthwise and transversely into small pieces to facilitate preservation and

ensure the preservative reached them. The liver sections were preserved in 10% formalin in clean, sterile glass containers, tightly sealed for 48 hours until histological sectioning was performed to prepare tissue sections for the study (44). The liver samples to be studied histologically were fixed using 10% formalin. After 48 hours, the samples were removed from the containers and washed several times with water. Water was gradually withdrawn from the liver tissue by passing the samples through a series of ascending concentrations of ethyl alcohol, starting with (70%, 80%, 90%, 100%, 100%) for two hours for each concentration. The samples were pre-cleaned by placing them in pure xylene twice for five minutes each time to make the samples more transparent and to remove the oxidizing material. The samples were then transferred to glass bottles containing a mixture of molten paraffin wax and xylene in a 1:1 ratio in an electric oven at a temperature of 59-60°C for half an hour, then transferred to other bottles containing molten paraffin wax and the wax was replaced twice for (1-1.5) hours each time to ensure that the samples were completely saturated with the wax. Wax molds containing the sample were prepared by immersing the sample in special iron molds filled with paraffin wax. A heated needle was used to remove bubbles around the samples. The samples were left to solidify at laboratory temperature, then separated from the mold and stored until the sectioning stage. The wax molds were trimmed with a sharp razor, then the wax mold containing the sample was fixed in a rotary microtome for cutting into ribbon sections with a thickness of 5-6 micrometers. The strips were then transferred to a water bath at 45-50°C for 1-2 minutes to ensure good spreading of the tissue sections. The tissue sections were then located on glass slides and left to dry on a warm plate at 37°C for an hour, after which they were left at laboratory temperature till day after today. The tissue sections had been stained with hematoxylin-eosin stain. After staining, the tissue sections have been hooked up with DPX Plasticizer (Xylene Ditrine) to steady the coverslips and ensure a clear refractive index. The slides were then left on a hot plate for 8 hours to dry and be equipped for microscopic examination. After mounting and drying the glass slides, the tissue sections were tested to determine the modifications that occurred inside the studied tissues using a light microscope at 40x magnification (44).

#### **Statistical analysis:**

Analysis of variance was performed the use of the one-way ANOVA approach using the SAS statistical application to examine the effect of the variables. Significant variances have been predicted at a significance level of ( $P \leq 0.05$ ) (45).

#### **RESULTS AND DISCUSSION:**

The results, shown in Table (1), indicated a Very significant increase ( $P \leq 0.05$ ) within the average concentrations of liver enzymes (AST, ALT, ALP) in group (G2), which received Orlistat at a concentration of 32 mg/kg/day for 30 days, as compared to (G1). The results of our study also indicated a significant decrease ( $P \leq 0.05$ ) in the levels of AST, ALT, and ALP in the group (G3), the aqueous extract group of Agrimony (AE) at a concentration of 400 mg/kg/day, and the group (G4), the extract group with Orlistat (ORL+AE), compared to the drug group (G2). The results of our study are consistent with the results of studies by (46), who indicated that orlistat caused a decrease in total protein (TP) and an increase in liver enzymes (AST, ALT, ALP) when male rats were given ORL (60 mg/kg) for six weeks. A previous study confirmed the negative effect of ORL, which caused a decrease in albumin (Alb) levels (47). Another previous study indicated a decrease in protein and albumin levels when rats were treated with orlistat ORL at a dose of 43.3 mg/kg. For six weeks (48). The results of our study are also consistent with those of (49), who demonstrated that orlistat ORL (4 mg/kg) decreased globulin and albumin (Alb, Glo) 30 days after laboratory rats were treated with the drug. A previous study also agreed with our current results, stating that treatment of adult male rats with Orlistat at a concentration of 32 mg/kg/day for 30 days resulted in severe liver injury and, consequently, increased liver enzyme activity (37). The results of this study are also consistent with those of (34), who observed an increase in liver enzyme levels and the occurrence of acute and direct liver injury when male laboratory rats were treated with orlistat. The results of our study are consistent with the results of the study (50) conducted on patients consuming the drug Orlistat (120). They recorded numerous cases of severe liver injury and a sharp rise in liver enzymes after taking Orlistat for 2-12 weeks. Although the concentrations of the drug used varied in the above studies, they all indicated similar results indicating the drug's toxicity when taken at an excessive dose (higher than the safe therapeutic dose) and its effect on some liver function parameters, especially the rise in liver enzyme levels (AST, ALT, ALP) in the blood serum of adult male albino laboratory rats treated with Orlistat.

Sections of the control group (G1) showed normal hepatocytes, and the central vein was intact without any necrosis and clear sinusoids arranged radially around the central vein (Figure 1). Sections of the second group (G2) treated with Orlistat at a concentration of 32 mg/kg once a day (Figure 2) showed hemorrhage, inflammatory cells,



degeneration of some cells, severe and clear congestion of the central vein, expansion of the sinusoids, infiltration of inflammatory cells, and the hepatocyte membranes appeared irregular (37). observed similar changes as a result of treating male white rats with the same dose of the drug, explaining that cell infiltration stimulates the inflammatory mediator (TNF- $\alpha$ ), which may lead to paracrine liver damage (37). A previous study also indicated similar changes in liver tissue as a result of dosing male rats with orlistat (32 mg/kg) for 6 weeks, as they confirmed the appearance of hepatocytes with degenerated cytoplasm with numerous vacuoles, dark nuclei, and an increase in Kupffer cells (35).

However, the results of the current study did not agree with those (51), as their study results indicated the drug's effectiveness in reducing the levels of both AST and ALT when male rats treated with a high-fat diet (obese) were dosed with orlistat at a concentration of 12 mg/kg daily for 30 days.

The results of the current study also did not agree with those of (52), who indicated that the drug was effective in reducing the level of the ALP enzyme when rats were dosed with it at a concentration of 20 mg/kg daily. This indicates that the concentration of the drug dose relative to body weight determines the extent of the damage caused by orlistat and its potential to cause physiological and tissue changes in the body, especially the liver (53). Due to its excessive metabolic rate and direct exposure to pollutants, the liver is directly liable to oxidative stress (54). Oxidative stress is the most common motive of drug-brought on hepatotoxicity (55). Reactive oxygen species (ROS) can harm all varieties of liver cells (54). This damage is because of an imbalance among multiplied ROS manufacturing and decreased antioxidant hobby (56). During oxidative pressure, lipids in cell membranes are oxidized, leading to membrane disruption. This lipid oxidation is accompanied by way of the production of reactive fatty aldehydes, such as malondialdehyde. Oxidative strain is also acknowledged to induce inflammation with the aid of stimulating the production of inflammatory cytokines and growing nitric oxide synthesis (57). Elevated oxidative pressure and impaired antioxidant structures contribute to hepatocyte damage. Reactive oxygen species (ROS) can damage cellular structures, which include DNA, lipids, and proteins, and promote inflammation and fibrosis. ROS-precipitated mitochondrial disorder can exacerbate oxidative pressure and contribute to the progression of liver sickness (58).

Elevated liver enzymes in institution II (G2) sufferers dealt with orlistat are because of oxidative strain due to the era of unfastened radicals that cause lipid peroxidation, a primary reason of hepatic cellular damage and hemolysis. This release of liver enzymes into the bloodstream effects from damaged cell membranes, extended permeability, and infiltration of

those enzymes into the bloodstream, leading to extended serum stages (34). Severe liver injury following orlistat intake also can be explained with the aid of the drug's pastime and ability to inhibit the liver detoxification enzyme carboxylesterase-2, which causes multiplied serum liver enzymes and liver failure (46). ORL reasons oxidative pressure that is dose-related, with a dose of 32 mg/kg being the number one purpose of oxidative strain-prompted hepatotoxicity. This reasons oxidative damage to lipids, proteins, and DNA (27). The results of the present day look at are constant with the ones of (19), who researched male rats that have been orally dosed with an extract of the A. Eupatoria (AE) at a concentration of 100-300-600 mg/kg over two weeks. The take a look at introduced that the six hundred mg/kg dose became the most effective at lowering liver enzymes. The results of the cutting-edge study are also consistent with the findings of (38), who indicated a decrease in liver enzyme concentrations when male albino rats had been orally dosed with an alcoholic and aqueous extract of the A. Eupatoria (AE) at a attention of 400 mg/kg. The effectiveness of agrimony (AE) is because of the hobby of its chemicals, as it incorporates a massive wide variety of biologically active substances consisting of flavonoids and luteolin (22). Polyphenols represent the main components of the plant, which includes phenolic acids, flavonoids, tannins, procyanidins, and coumarins, similarly to terpenoids, steroids, and saponins (16). A. Eupatoria has additionally been shown to contain Para coumaric acid, which has proven anti-inflammatory pastime, liver-protecting outcomes, and lipid-decreasing consequences (59). The results of our study, shown in Table (2), also indicated a significant decrease ( $P \leq 0.05$ ) in the levels of proteins (total protein TP, albumin Alb, and globulin Glo) in the positive control group (G2) compared to the negative control group (G1), and a significant increase ( $P \leq 0.05$ ) in the levels of these proteins (TP, Alb, and Glo) in the AE plant group (G3) and the plant group with the drug ORL+AE (G4) compared to the positive control group (G2).

Histological sections of the plant group at a concentration of 400 mg/kg showed liver tissue with a normal cellular structure similar to the control sections (Figure 3). Sections of the plant group at a concentration of 400 mg/kg and treated with Orlistat showed a significant improvement in the histological changes that occurred in the drug group, represented by the appearance of weak inflammation, reduced degeneration, slight congestion in the central vein, and a reduction in the infiltration of inflammatory cells Figure (4) compared with the images of the sections of the control group (G2). Our results are consistent with the results of (19), who indicated in their study the appearance of an improvement in the cellular structure of liver tissue, especially a decrease in

the number of inflammatory cells and necrosis, and confirmed the ability of Agrimony to reduce the severity of bleeding and congestion. A previous study also indicated that consuming AE extract at a preventive dose (200-400-800 mg/kg) reduced hepatic cell necrosis and reduced the infiltration of inflammatory cells around the central vein (38).

The results of our study are consistent with those of (46), who indicated that Orlistat caused a decrease in total protein (TP) when rats were given ORL (60 mg/kg) for six weeks. A previous study (47), confirmed the negative effect of ORL, which caused a decrease in albumin (Alb) levels. (48) also indicated a decrease in protein and albumin levels when rats were treated with ORL (43.3 mg/kg) for six weeks. Finally, our study is consistent with that of (49), who demonstrated that ORL (4 mg/kg) led to a decrease in globulin and albumin levels after 30 days of drug administration in laboratory rats. Our study also agrees with the results of a previous study (60) regarding the effect of agrimony, which indicated that AE can improve biomarkers (Alb, TP), which were impaired by CCL4 (10 mg) for six days. A previous study also indicated that consuming aqueous agrimony extract at concentrations of 100-300-600 mg/kg for two weeks increased total protein and albumin levels (19). Finally, our study is consistent with the findings of a study (61) conducted on 80 patients with elevated ALT, which indicated that consuming an AE capsule (40 mg daily for two months) improved total protein and TP levels, bringing them to normal. *A. eupatoria* (AE) demonstrated a clear protective role against liver damage through its ability to reduce liver enzyme levels and improve hepatic protein levels by increasing albumin, globulin, and total protein. The plant's effectiveness is attributed to its high content of flavonoids and derivatives such as luteolin, apigenin, kaempferol, and quercetin (62). Flavonoids are phytochemical compounds with therapeutic effects that protect against many diseases. Neohesperidin, hesperidin, and hesperetin are acidic flavonoids with anti-inflammatory and antioxidant activities (63). The active compounds in AE reduce levels of liver transaminase enzymes, lipid peroxidation, and inflammatory cytokines by regenerating glutathione, removing reactive oxygen species, and modulating levels of antioxidant enzymes. This reduces oxidative stress (64). The plant's ability to improve transaminase levels may be due to the abundance of gallic and ellagic acids (22). The effectiveness of Agrimony and its ability to inhibit inflammatory markers in hepatic cells can be explained by its high content of coumarins, flavonoids, tannins, terpenoids, and phenolic compounds, including protocatechuic acid, p-coumaric acid, chlorogenic acid, quercitrin, and gallic acid (65). This is consistent with what was stated by (66), They confirmed the effectiveness of the protective role of AE at a concentration of (30-10-100-300) mg/kg against ethanol-induced hepatotoxicity in rats

**Table 1:** shows the effect of the Aqueous extract of *Agrimonia eupatoria* L. (400) mg/kg and the extract group treated with Orlistat on some Liver enzymes in the serum of rats for 30 days.

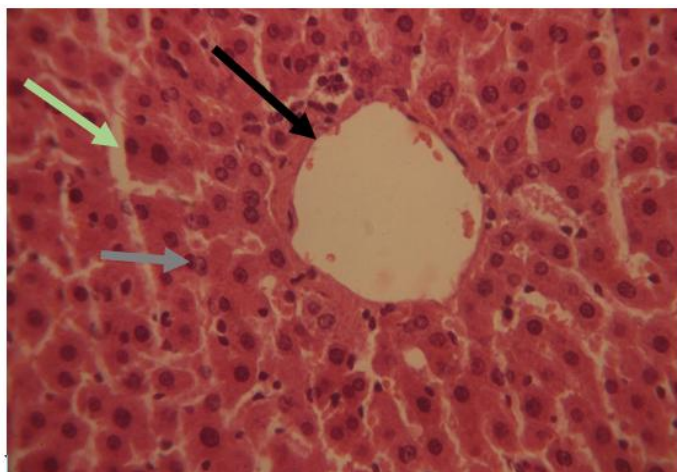
groups	AST (IU/ L)	ALT (IU/ L)	ALP (IU/ L)
(G1) Negative control group treated with Distilled water	22.57 ±0.65 B	23.45±1.57 B	48.00±2.79 B
(G2) positive control group treated with Orlistat (32) mg/kg	118.59± 2.16 A	55.74±1.94 A	178.02±5.36 A
(G3) Aqueous extract group of Agrimonia at a (Ghafis) dose (400) mg/kg	21.91± 0.54 B	23.71±0.78 B	45.25±1.07 B
(G4) Group of aqueous extract of Agrimonia (Ghafis) (400) mg/kg treated with Orlistat (32) mg/kg	39.49±0.84 C	34.37±0.65 C	54.39±1.69 C
LS. D	3.37	3.23	7.33

Values represent the mean ± standard error.  
Different letters in a column indicate a significant difference ( $P \leq 0.05$ ) between groups.  
Means with the same letters (A) within a column are not significantly different.  
Means with different letters (B, C) within a column are significantly different

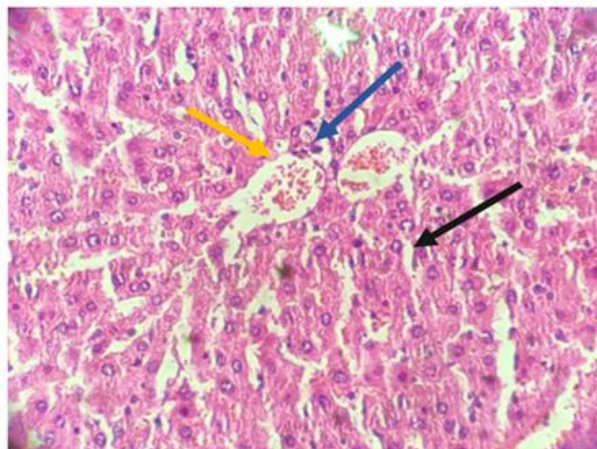
**Table 2:** shows the effect of the Aqueous extract of *Agrimonia eupatoria* L. (400) mg/kg and the extract group treated with Orlistat on some Proteins in the serum of rats for 30 days.

Groups	T.P mg/dl	Albumin mg/dl	Globulin mg/dl
(G1) Negative control group treated with Distilled water	6.10±0.28 A	3.24±0.26 A	3.74±0.17 A
(G2) positive control group treated with Orlistat (32) mg/kg	4.56±0.07 B	1.31±0.17 B	2.53±0.17 B
(G3) Aqueous extract group of Agrimonia at a dose (400) (Ghafis) mg/kg	6.41±0.32 A	3.09±0.22 A	3.95±0.17 A
(G4) Group of aqueous extract of Agrimonia (Ghafis) (400) mg/kg treated with Orlistat (32) mg/kg	5.76±0.10 A	3.58±0.16 A	3.74±0.20 A
LS. D	0.61	0.60	0.55

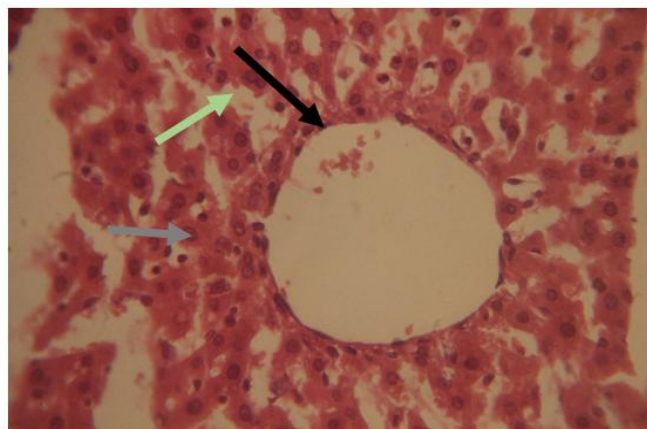
Values represent the mean ± standard error.  
Different letters in a column indicate a significant difference ( $P \leq 0.05$ ) between groups.  
Means with the same letters (A) within a column are not significantly different.  
Means with different letters (B) within a column are significantly different.



**Figure 1.** A cross-section of the liver tissue of the control group showing hepatocytes (gray arrow) and the central vein (black arrow) sinusoids (green arrow). No necrosis is visible. (H&E stain, 40x magnification).

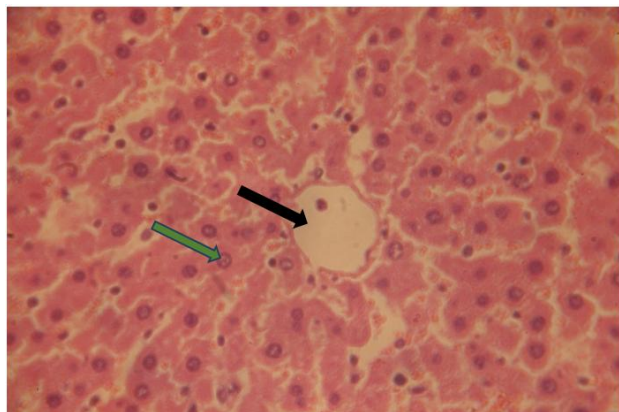


**Figure 2.** Cross section of liver tissue from group II treated with orlistat showing dilated central vein congestion, degeneration of some cell (necrosis) (black arrow), inflammatory cells (blue arrow), and severe congestion (yellow arrow), (H&E stain, 40x magnification).



**Figure 3.** Cross section of liver tissue of the plant group showing the normal structure of liver tissue, hepatocytes (gray arrow), central vein (black arrow), and sinusoids are normal (green arrow) (H&E stain, 40x magnification).





**Figure 4.** A cross-section of the liver tissue of the control group showing return the tissue to its normal state and the central vein (black arrow) hepatocytes (green arrow).

### CONCLUSION:

In conclusion, the results of our study confirmed that the drug orlistat (ORL) has negative effects at a concentration of 32 mg/kg, causing significant toxicity and liver damage, as measured by liver enzyme and protein levels. Conversely, agrimony (AE) has been shown to have protective effects and the ability to protect the liver from drug-induced toxicity. The protective effect of agrimony is attributed to its active compounds, which contain high levels of coumarin, flavonoids, tannins, terpenoids, phenolic compounds, protocatechuic acid, p-coumaric acid, chlorogenic acid, quercitrin, gallic acid, and others. Furthermore, it has antioxidant properties, which inhibit lipid peroxidation and increase antioxidant levels. This result supports the hypothesis that medicinal plants are rich in active chemicals that can prevent or inhibit liver toxicity resulting from toxic drug doses.

### REFERENCE:

- 1) Pastore, R., and Roviello, G. N. (2023). *Georgian Medicinal Plants as Rich Natural Sources of Antioxidant Derivatives: A Review on the Current Knowledge and Future Perspectives*.
- 2) Barkat, M. A., Goyal, A., Barkat, H. A., Salaudhin, M., Pottoo, F. H., and Anwer, E. T. (2021). Herbal medicine: Clinical perspective and regulatory status. *Combinatorial chemistry & high throughput screening*, 24(10), 1573-1582.
- 3) El Hajj, M., and Holst, L. (2020). Herbal medicine use during pregnancy: A review of the literature with a special focus on Sub-Saharan Africa. *Frontiers in pharmacology*, (11), 866.
- 4) Gershenson, J., and Ullah, C. (2022). Plants protect themselves from herbivores by optimizing the distribution of chemical defenses. *Proceedings of the National Academy of Sciences*, 119(4), e2120277119.
- 5) Agu, K. C., Okolie, N. P., Falodun, A., and Engel-Lutz, N. (2018). In vitro anticancer assessments of *Annona muricata* fractions and in vitro antioxidant profile of fractions and isolated acetogenin (15-acetyl guanacone). *Journal of Cancer Research and Practice*, 5(2), 53-66.
- 6) Veiga, M., Costa, E. M., Silva, S., and Pintado, M. (2020). Impact of plant extracts upon human health: A review. *Critical reviews in food science and nutrition*, 60(5), 873-886.
- 7) Upton, R., David, B., Gafner, S., and Glasl, S. (2020). Botanical ingredient identification and quality assessment: strengths and limitations of analytical techniques. *Phytochemistry Reviews*, 19(5), 1157-1177.
- 8) Mehraj, N., and Alam, M. (2024). An Ghafis (*Agrimonia eupatoria*): An In-depth Review of its Historical Context, Therapeutic Properties, Ethnopharmacological Applications, and Scientific Research. *International Journal of Medical Sciences and Pharma Research*, 10(1), 35-38.
- 9) Tsigotis-Maniecka, M., Pawlaczyk-Graja, I., Ziewiecki, R., Balicki, S., Matulová, M., Capek, P., ... and Gancarz, R. (2019). The polyphenolic-polysaccharide complex of *Agrimonia eupatoria* L. as an indirect thrombin inhibitor-isolation and chemical characterization. *International journal of biological macromolecules*, (125), 124-132.
- 10) Malheiros, J., Simões, D. M., Figueirinha, A., Cotrim, M. D., and Fonseca, D. A. (2022). *Agrimonia eupatoria* L.: An integrative perspective on ethnomedicinal use, phenolic composition, and pharmacological activity. *Journal of Ethnopharmacology*, (296), 115498.
- 11) Paluch, Z., Biriczova, L., Pallag, G., Marques, E. C., Vargova, N., and Kmoníčková, E. (2020). The therapeutic effects of *Agrimonia eupatoria* L. *Physiological Research*, 69(Suppl 4), S555.
- 12) Milani, F., Muratore, C., Biella, S., Bottoni, M., Rossi, E., Colombo, L., ... and Fico, G. (2025). From Traditional Medicine to the Laboratory: A Multidisciplinary Investigation on *Agrimonia eupatoria* L. Collected in Valle Imagna (BG, North of Italy). *Plants*, 14(3), 1-33.
- 13) García-Oliveira, P., Fraga-Corral, M., Pereira, A. G., Lourenço-Lopes, C., Jimenez-Lopez, C., Prieto, M. A., and Simal-Gandara, J. (2020). Scientific basis for the



- industrialization of traditionally used plants of thánflammatory and hepatoprotective properties. *Plants*, Rosaceae family. *Food Chemistry*, 330, 127197. 11(18), 2371.
- 14) Pour, M. G., Mirazi, N., Moradkhani, S., Rafieian23) Pukalskienė, M., Slapšytė, G., Dedonytė, V., Kopaei, M., and Rahimi-Madiseh, M. (2020). *Alazutka*, J. R., Mierauskienė, J., and Venskutonis, P. R. comprehensive review on phytochemical(2018). Genotoxicity and antioxidant activity of five pharmacological and therapeutic properties oAgrimonia and Filipendula species plant extracts evaluated Agrimonia eupatoria L. *Journal of Herbmēdy comet and micronucleus assays in human lymphocytes Pharmacology*, 10(1), 14-30. and Ames Salmonella/microsome test. *Food and Chemical Toxicology*, (113), 303-313.
  - 15) Akbar, S., and Akbar, S. (2020). Agrimonia eupatoriaL. (Rosaceae) (Syn.: Agrimonia officinalis Lamarck). 24) Koo, H. C., Tan, L. K., Lim, G. P., Kee, C. C., and Omar, M. A. (2023). Obesity and its association with undiagnosed diabetes mellitus, high blood pressure, and hypercholesterolemia in the Malaysian adult population: A national cross-sectional study using NHMS Data. *International Journal of Environmental Research and Public Health*, 20(4), 3058.
  - 16) Ginovyan, M., Ayvazyan, A., Nikoyan, A., Tumanyan, L., and Trchounian, A. (2020). Phytochemical screening and detection of antibacterial components from crude extracts of some Armenian herbs using the TLC-bioautographic technique. *Current Microbiology*, (77), 1223-1232. 25) Qi, X. (2018). Review of the clinical effect of Orlistat. In IOP Conference Series: *Materials Science and Engineering*, 301, 012063.
  - 17) Şener, S. Ö., Ciliz, E., Öztekin, B. N., Badem, M., and Özgen, U. (2022). Investigation of selected medicinal plants for their anti-obesity properties. *Turkish Journal of Pharmaceutical Sciences*, 19(5), 498. 26) Aydin, B., and Onbasi, K. (2021). Lipase inhibitor orlistat: An old but still effective weapon. *Medicine Science*, 10(4).
  - 18) Běložníková, K., Sladkovská, E., Kavan, D., Hýšková, V., Hodek, P., Šmíd, D., and Ryšlavá, H. (2023). Effect of Agrimonia eupatoria L. and Origanum vulgare L. Leaf, Flower, Stem, and Root Extracts on the Survival of Pseudomonas aeruginosa. *Molecules*, 28(3), 1019. 27) Kassab, A. A., Moustafa, K. A. A., and Abd-El-Hafez, A. A. (2020). The possible protective role of pumpkin seed oil in ameliorating tongue mucosal damage induced by Orlistat in adult male albino rats: A light and scanning electron microscopic study. *Egyptian Journal of Histology*, 43(4), 975-987.
  - 19) Moshtaghi, F., Azadbakht, M., Vaezi, G., and Hojati, S. A. M. V. (2022). The Hepatoprotective Effect of Agrimonia Eupatoria on Hepatotoxicity Caused by Pyrrolizidine Alkaloids In Senecio Vulgaris Extract In Male Rats. *Journal of Pharmaceutical Negative Results*, 13(9), 2130-2143. 28) Hou, X. D., Qin, X. Y., Hou, J., Tang, H., and Ge, G. B. (2022). The potential of natural sources for pancreatic lipase inhibitors: a solution to the obesity crisis. *Expert Opinion on Drug Discovery*, 17(12), 1295-1298.
  - 20) Olivero-Verbel, J., Quintero-Rincón, P., and Caballero-Gallardo, K. (2024). Aromatic plants as cosmeceuticals: benefits and applications for skin health. *Planta*, 260(6). 132. 29) Adeyemi, W. J., Olayaki, L. A., Abdussalam, T. A., Ige, S. F., Okesina, B. K., Abolarin, P. O., ... and Opabode, A. O. (2020). Comparative evaluation of the pharmacological value of virgin coconut oil, omega-3 fatty acids, and Orlistat in an experimental study on obesity with normo/hyper-lipidaemic diet. *PharmaNutrition*, (13), 100192.
  - 21) Tripathi, N., Goel, B., Bhardwaj, N., Sahu, B., Kumar, H., and Jain, S. K. (2022). Virtual screening and molecular simulation study of natural products database for lead identification of novel coronavirus main protease inhibitors. *Journal of Biomolecular Structure and Dynamics*, 40(8), 3655-3667. 30) Zhu, J., Hu, M., Liang, Y., Zhong, M., Chen, Z., Wang, Z., ... and Yang, C. (2024). Pharmacovigilance analysis of Orlistat adverse events based on the FDA adverse event reporting system (FAERS) database. *Heliyon*, 10(14).
  - 22) Huzio, N., Grytsyk, A., Raal, A., Grytsyk, L., and Koshovyi, O. (2022). Phytochemical and pharmacological research in Agrimonia eupatoria L. herb extract with anti- 31) Uehira, K., and Unno, H. (2023, July). Study on the recognition technology of QR code superimposed on

- images using GAN. In *2023 7th International Conference on Imaging, Signal Processing and Communications (ICISPC)*, 6-10. IEEE.
- 32) Sari, A. (2019). Nephrotoxic Effects of Drugs Poisoning in the Modern World-New Tricks for an Old Dog.
  - 33) Cui, X., Chen, X., Li, Y., Fu, X., Song, P., Xiao, L., ... and Yuan, S. (2022). Oxalate crystal-related acute renal injury caused by orlistat: A case report. *Zhongnan da xue xue bao. Yi Xue ban Journal of Central South University. Medical Sciences*, 47(5), 583-587.
  - 34) Al-Jubouri, W. Y. A., and Rashid, M. S. (2024). Histological and Physiological evaluation of Hydroxycut and Refit orlistat hepatotoxicity in male albino rats. *Samarra Journal of Pure and Applied Science*, 6(3), 169-180.
  - 35) Kandil, E., and Arisha, S. (2022). Hepatorenal and cerebellar anti-toxic effects of curcumin against Orlistat-associated toxicity in obese male albino rats. *International Journal of Cancer and Biomedical Research*, 6(4), 13-30.
  - 36) Chakravarty, H. (1976). *Plant Wealth of Iraq: A Dictionary of Economic Plants*. Botany Directorate, Ministry of Agriculture & Agrarian Reform.
  - 37) Fahmi, M. A. (2021). A Histological Study on The Effect of Orlistat Administration on the Liver of the Adult Male Albino Rat and the Possible Protective Effect of Vitamin C. *Alexandria Journal for Veterinary Sciences*, 70(1).
  - 38) Khazaei, M., and Mirazi, N. (2018). The effect of Agrimonia eupatoria leaf hydroalcoholic extract on carbon tetrachloride-induced liver toxicity in male rats. *Journal of Advances in Medical and Biomedical Research*, 26(114), 84-97.
  - 39) Athyros, V. G., Tziomalos, K., Gossios, T. D., Griva, T., Anagnostis, P., Kargiotis, K., ... and Mikhailidis, D. P. (2010). Safety and efficacy of long-term statin treatment for cardiovascular events in patients with coronary heart disease and abnormal liver tests in the Greek Atorvastatin and Coronary Heart Disease Evaluation (GREACE) Study: a post-hoc analysis. *The Lancet*, 376(9756), 1916-1922.
  - 40) Belfield, A., and Goldberg, D. M. (1971). Revised assay for serum phenyl phosphatase activity using 4-amino-antipyrine. *Enzyme*, 12(5), 561-573.
  - 41) Young, D. S (2001). Effects of disease on clinical laboratory tests. *Book*.
  - 42) Young, D. S. (1997). Effects of drugs on clinical laboratory tests. *Annals of clinical biochemistry*, 34(6), 579-581.
  - 43) Tietz, N.W. (1999). *Textbook of clinical chemistry*: W.B. Saunders Company, Philadelphia, 490-191.
  - 44) Suvarna, K. S., Layton, C., and Bancroft, J. D. (2018). Bancroft's theory and practice of histological techniques. *Elsevier health sciences*.
  - 45) Moder, K. (2010). Alternatives to the F-test in one-way ANOVA in case of heterogeneity of variances (a simulation study). *Psychological Test and Assessment Modeling*, 52(4), 343.
  - 46) Ledesma-Aparicio, J., Mailloux-Salinas, P., Arias-Chávez, D. J., Campos-Pérez, E., Calixto-Tlacomulco, S., Cruz-Rangel, A., ... and Bravo, G. (2024). Transcriptomic Analysis of the Protective Effect of Piperine on Orlistat Hepatotoxicity in Obese Male Wistar Rats. *Journal of Biochemical and Molecular Toxicology*, 38(11), e70040.
  - 47) Feng, X., Lin, Y., Zhuo, S., Dong, Z., Shao, C., Ye, J., and Zhong, B. (2023). Treatment of obesity and metabolic-associated fatty liver disease with a diet or orlistat: a randomized controlled trial. *The American Journal of Clinical Nutrition*, 117(4), 691-700.
  - 48) Javed, M., Ahmed, W., Khan, A., and Rabbani, I. (2023). Comparison of the efficacy of fermented garlic and orlistat (Lipase Inhibitor) in obesity management using an experimental rodent model. *Foods*, 12(21), 3905.
  - 49) Aljamal, A., Al Shawabkeh, M., Amawi, K., Alqadi, T., and Khwaldeh, A. (2023). Physiological Effects of Fig Leaf Extract and Orlistat on Obesity, Kidney, and Liver of Rats. *Pakistan Journal of Biological Sciences: PJBS*, 26(9), 458-462.
  - 50) Brown, S. A., Izzy, M., and Watt, K. D. (2021). Pharmacotherapy for weight loss in cirrhosis and liver transplantation: translating the data and underused potential. *Hepatology*, 73(5), 2051-2062.
  - 51) Hamza, R. Z., and Alsolami, K. (2023). Ameliorative effects of Orlistat and metformin, either alone or in combination, on liver functions, structure, immunoreactivity, and antioxidant enzymes in experimentally induced obesity in male rats. *Heliyon*, 9(8).
  - 52) Deng, Z., Meng, C., Huang, H., Song, S., Fu, L., and Fu, Z. (2022). The different effects of

- psyllium husk and Orlistat on weight control, the amelioration of hypercholesterolemia and non-alcoholic fatty liver disease in obese mice induced by a high-fat diet. *Food & function*, 62(13)(17), 8829-8849.
- 53) Al-Safo, A. A., and Al-Duliami, L. H. (2022). Histopathological Study of Orlistat and Rosemary Aqueous Extract in the Brain and Liver of Obese Male Rats. *Journal of Applied Veterinary Sciences*, 7(2), 34-40.
- 54) Sharma, P., Nandave, M., Nandave, D., Yadav, S., Vargas-De-La-Cruz, C., Singh, S., ... and Behl, T. (2023). Reactive oxygen species (ROS)-mediated oxidative stress in chronic liver diseases and its mitigation by medicinal plants. *American Journal of Translational Research*, 15(11), 6321.
- 55) Azarmehr, N., Afshar, P., Moradi, M., Sadeghi, H., Sadeghi, H., Alipoor, B., ... and Doustimotlagh, A. H. (2019). Hepatoprotective and antioxidant activity of watercress extract on acetaminophen-induced hepatotoxicity in rats. *Heliyon*, 5(7).
- 56) Al-Abdaly, Y. Z., Saeed, M. G., and Al-Hashemi, H. M. (2021). Effect of methotrexate and aspirin interaction and its relationship to oxidative stress in rats. *Iraqi Journal of Veterinary Sciences*. 35(1), 151-156.
- 57) Srivastava, R., and Srivastava, P. (2018). Hepatotoxicity and the role of some herbal hepatoprotective plants in the present scenario. *GJ Dig Dis*, 3(2), 2.
- 58) Videla, L. A., and Valenzuela, R. (2022). Perspectives in liver redox imbalance: toxicological and pharmacological aspects underlying iron overloading, nonalcoholic fatty liver disease, and thyroid hormone action. *Biofactors*, 48(2), 400-415.
- 59) Shen, Y., Song, X., Li, L., Sun, J., Jaiswal, Y., Huang, J., ... and Guan, Y. (2019). Protective effects of p-coumaric acid against oxidant and hyperlipidemia-an in vitro and in vivo evaluation. *Biomedicine & Pharmacotherapy*, 111, 579-587.
- 60) Park, S. J., Hong, N. I., and Cho, M. J. (2020). Hepatoprotective effects of Agrimonia eupatoria L. extract on CCl4-induced acute liver injury in mice. *KALAS Winter Symposium*, (1), 117-117.
- 61) Cho, Y. M., Kwon, J. E., Lee, M., Lea, Y., Jeon, D. Y., Kim, H. J., and Kang, S. C. (2018). Agrimonia eupatoria L. (Agrimony) extract alters liver health in subjects with elevated alanine transaminase levels: a controlled, randomized, and double-blind trial. *Journal of medicinal food*, 21(3), 282-288.
- Karlińska, E., Romanowska, B., and Kosmala, M. (2021). The aerial parts of Agrimonia procera Wallr. And Agrimonia eupatoria L. as a source of polyphenols, and especially agrimoniin and flavonoids. *Molecules*, 26(24), 7706.
- Ortiz, A. D. C., Fideles, S. O. M., Reis, C. H. B., Bellini, M. Z., Pereira, E. D. S. B. M., Pilon, J. P. G., ... and Buchaim, R. L. (2022). Therapeutic effects of citrus flavonoids neo hesperidin, hesperidin, and its aglycone, hesperetin, on bone health. *Biomolecules*, 12(5), 626.
- 64) Gracia-Sancho, J., Caparrós, E., Fernández-Iglesias, A., and Francés, R. (2021). Role of liver sinusoidal endothelial cells in liver diseases. *Nature Reviews Gastroenterology & Hepatology*, 18(6), 411-431.
- 65) Singh, P., Prajapati, N., Prajapati, N., Roji, A., and Mishra, S. (2022). Review On Hepatoprotective Properties of Indigenous Medicinal Plants Against Liver Toxicity. *World Journal of Pharmaceutical Research*, 11, 825-842. (2277– 7105).
- 66) Yoon, S. J., Koh, E. J., Kim, C. S., Zee, O. P., Kwak, J. H., Jeong, W. J., ... and Lee, S. M. (2012). Agrimonia eupatoria protects against chronic ethanol-induced liver injury in rats. *Food and Chemical Toxicology*, 50(7), 2335-2341.