

# A comparison of the abomasum's histology and histochemistry between Awassi (*Ovis aries awassi*) and Hamdani (*Ovis aries hamdani*) Sheep

Hussain Ahmed Ibrahim and Khalid Hadi Kadhim

College of Veterinary Medicine, University of AL-Muthanna , Iraq.

Corresponding author: dr-kh8195@ mu.edu.iq

**Received:** 17/3/2025

**Accepted:** 29/3/2026

**Published:** 15/6/2026

**Abstract**— The study was investigation to characterize and compare the histological architecture and histochemical characteristics of the abomasum between Hamadani and Awassi sheep. Ten samples of abomasum from each animal, and five specimens (0.8 cm) from each of the portion of abomasum. According to the study, all animals had three regions in the abomasum: the cardiac, fundic, and pyloric. The glands in the lamina propria of each region were different from one another; the fundus region were covered by correct gastric glands, which had no folds in the mucosa as well as deep gastric pits alongside long glands, while the cardiac glands were mucus-secreting, shallow pits, and short glands with pale, smooth mucosa. Because of the well-developed gastric rugae, which are lined with pyloric glands that secrete mucus and have deeper pits but shorter glands than the fundic region, the mucosa is reddish, and thick. The mucosa looks to be extensively folded, and the pyloric canal is lined with many rugae. Internal, the pyloric sphincter produces a clear circular ring. Awassi sheep often eat higher-energy diets, have thicker abomasal layers, and have higher metabolism and digestive demands. They also need quicker digestion and absorption for milk production and growth. Hamdani sheep have an effective digestive system and are suited to eating poor-quality feed. Rich foods promote increased production of enzymes and acids, as well as increased activity of the gastric glands. The final layer, the tunica serosa, is made of connective tissue that is loose and has blood vessels, while the tunica muscularis appears as circular as well as longitudinal layers. muscle layer thickening to improve stomach emptying, mixing, and motility. According to histochemical data, the stomach cells' composition varied across the abomasal sections and between animals, with Awassi exhibiting a higher mucous secretion. With PAS and AB, the mucous cell mucin staining intensity is faint in the heart, moderate, and robust in the fundic and pyloric. In conclusion, The abomasal regions' varying interior and exterior surfaces correspond to their different digestive functions. The continuous effort to determine the degree of connection across sheep species is aided by this study, which revealed both similarities and variations in the histological architecture of the abomasum.

**Keywords** — Hamadani, Awassi, Abomasum, Comparison, Histomorphometric

## INTRODUCTION

Based on their habitats, the animals are divided into different categories. For example, land animals, like sheep, cattle, and camels, live in houses and dairy farms. Wild animals, such as lions and elephants, are classified as wild because they have not been domesticated by humans. Additionally, they rely on a mutually beneficial relationship with a colony of microbes, mostly bacteria with fibrolytic ability, in either their hindgut, which includes the cecum along with colon of non-ruminant herbivores, or their foregut, which includes the rumen of ruminants and pseudo-ruminants, for the digestion of fiber (1,2). One of the most significant mammals, sheep are bred mostly for their meat, wool, hair, milk, and hides. You can also use their waste elements to make fertilizer. In Mesopotamia, the birthplace of civilizations, wherein agriculture and animal husbandry have thrived since antiquity, sheep have been raised in Iraq for thousands of years (3,4). Approximately sixty percent of Iraqi sheep are Awassi, the most well-known and dominating variety in the country, and they frequently attain higher body weights. Due to its high pairing rate, big frame frame, heavy fleece weight, and frequently colored and coarse fibers, as well as its large ears, wide range pendulous, and lack of horns in both sexes, the Hamadani sheep has become one of the most significant and preferred indigenous strains of Karadi sheep utilized by sheep owners. It is primarily classified as a fatty-tailed carpet-wool (5,6). When it comes to turning poor-quality feed into a substance with high nutritional value, ruminants' stomach is an essential digestive organ (7). Food enters the stomach, the third section of the digestive system, from the esophagus, where it is combined, broken down, and then sent in a smaller form to the small intestine. It has a significant impact on absorption and digestion. Numerous mucosubstances that can differ based on cell type, functional state, anatomical area, pathological condition, sex, age, and species are found in the gastric discharge of vertebrates. These mucosubstances can be detected using a variety of approaches (8,9). Affected animals' performance (meat, milk, and

reproductive potential) may be negatively impacted by abomasal lesions, which may also be directly linked to or proven to be the cause of mortality (10–14). There are few studies on sheep stomachs and how they function at a part of the digestive system. Study goals: Compare the study animals by doing histological analyses of the abomasum's inner and outer surfaces in the Awassi and Hamdani sheep. Learn about the variations in the histochemical characteristics of the fundic, pyloric, and cardiac abomasal parts between Awassi and Hamdani sheep.

## MATERIALS AND MTHODS

### Ethical approval

Every procedure was performed in compliance with the branch of histology and anatomy in College of Veterinary Medicine- AL-Muthanna university, Animal Care and Use Committee.

**Animals:** ten samples of abomasum from each animal taken from adult rams from Hamadani (*Ovis aries hamdani*) and Awassi (*Ovis aries awassi*); their ages 2-3 year were obtained by slaughterhouses in Al Muthanna province during (November 2025 for January 2026). All of the animals underwent a physical inspection to ensure their proper health. Following slaughter, the true stomach had been cut from the tip of the omasum to expose small intestine, that was then cleaned with tap water. Five samples (0.8 cm) from the cardiac, fundic, and pyloric sections of the abomasum were used for all histological and histochemical analyses. The work was done in the labs of the veterinary medicine collage, department of histology and anatomy at the Al-Muthanna University in Iraq.

**Histological and histochemical satins:** Hematoxylin and Eosin (H&E) to the histological features, Masson's trichrome to muscle and fibers of collagen, PAS for carbohydrates, PAS-AB for neutral carbohydrates, and AB for acidic carbohydrates, (15).

**STATISTICAL ANALYSIS;** The one-way analysis variable variance ( ANOVA ) tests were used to analyze the study at the 5% threshold for significance. The data was processed and controlled using social science statistical techniques (16).

## RESULT AND DISCUSSION

There were distinct cardiac, fundic, and pyloric areas within the simple columnar epithelium-lined abomasal mucosa (Fig. 1-4). According to (17), the smallest part was the cardiac gland, which was restricted to the omaso-abomasal orifice. Its glands appeared simple, branching, tubular, and coiled. Elevations known as gastric regions were seen in the mucosa of the fundic gland area, and gastric pits divided them from one another. Simple branching, tubular, and coiled in shape, the fundic glands contained a variety of mucous neck, chief, parietal, and endocrine cells. In contrast, the PAS response was higher toward the base of the stomach pits (Fig. 3-10). The development of mucosal immunity and enzymatic digestion in the early postnatal period depend heavily on the abomasum, sometimes referred to as the actual stomach of ruminants. Despite the fact that sheep are essential to the food security of emerging nations, little comparable data exists regarding the ontogenetic development of their abomasum, especially in native breeds (2,18).

Strong positive results for both acidic as well as neutral mucopolysaccharides were observed in the surface epithelial cells, with the latter being more prevalent. Glycogen and acidic and basic mucopolysaccharides were present in the pyloric area, where the surface epithelium cells were highly PAS positive (Fig. 3-6) this agree with (19). In order to back up milk production and development, Awassi sheep have thicker abomasal mucosa and muscle layers, which reflect increased metabolic and digestive demands. They also need faster digestion and more nutrient absorption. Large-bodied and extremely productive (20), Awassi sheep are chosen for their milk and meat and frequently eat diets high in energy, particularly in managed systems. Hamdani sheep have an effective digestive system but a less sturdy structure since they are acclimated to eating poor-quality feed in harsher, hilly conditions. Rich foods increase the release of acid and enzymes, as well as the activity of the stomach glands. Greater body weights are frequently attained by Awassi sheep, which results in thicker tissue (21,22). Organ development was improved by intensive upbringing. Tissue structural economy in extensive grazing systems. This explains why Hamdani sheep bred in conventional ways have thinner abomasal layers. Hamdani and Awassi sheep differ mostly in abomasal histomorphometry because of: Adaptive physiological reactions, metabolic and productivity demands, feeding schedule, and genetic background. Awassi sheep have thicker abomasal layers as a result of their increased digestive burden, while Hamdani sheep have a more economic gastrointestinal architecture that is better adapted to tougher conditions (Table 1). The digestive tract is the main site of water as well as nutrient absorption in animals and serves as an essential barrier against external chemicals. These essential processes mostly depend on the intestine epithelial cell barrier's integrity, which is made up of linked intestinal epithelial cells. The movement of foreign material via the intestinal lining can be facilitated by even little disruption to the epithelium (23,24). This area has a highly developed submucosal (Meissner's) plexus, which controls blood flow and secretion and helps to create a more substantial submucosal layer (Fig. 3), this agree with (2).

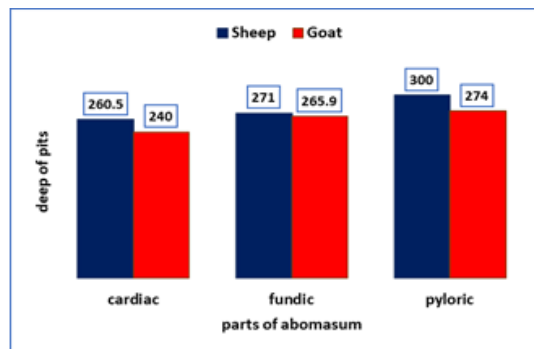
The tunica muscularis seems to be circular and longitudinal. thickening of the muscle layers to improve motility and mixing; improved gastric emptying and mechanical mixing. The final layer, the tunica serosa, is made of loose connective tissue, has fibroblast cells and blood vessels, and is encircled by mesothelium (Fig. 1,2,3,10). The serosa is thinner in the cardiac area, which is less mobile and mostly shielded by the surrounding forestomach compartments. The fundic region has the thickest tunica serosa because it is highly glandular, intraperitoneal, mobile, and requires a strong outer covering to protect and support the heavy mucosa and associated vascular supply. In contrast to the fundus area, the pyloric region's serosa is thinner and more supported by connective tissue and nearby tissues, which are described as smooth. The thickest serosa is seen in the fundic area (Table 1).

**Table 1.** Measurements wall layers of abomasum in Awassi and Hamdani Sheep,  $\mu\text{m}$

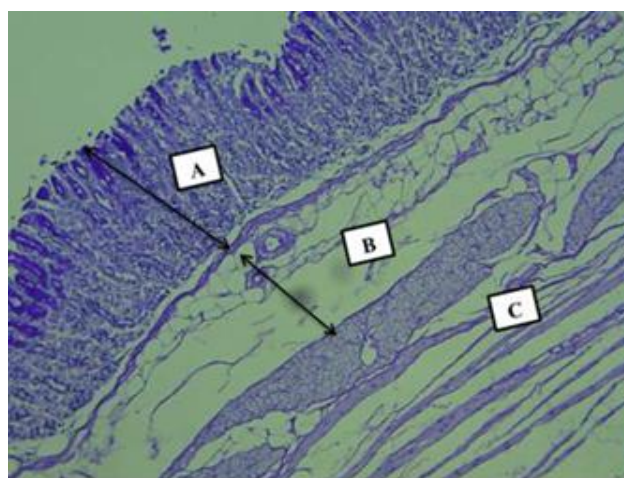
Tunica Part	Mucosa	Submucosa	Muscularis externa	Serosa
Cardiac in awassi hamadani	792 $\pm 0.3b$	371.5 $\pm 1.83b$	460.5 $\pm 3.53b$	66.6 $\pm 0.8b$
	711 $\pm 0.6b$	321.1 $\pm 1.3b$	420.8 $\pm 0.3b$	61.7 $\pm 0.2b$
Fundic in awassi hamadani	878.3 $\pm 0.9b$	457.9 $\pm 0.2b$	569.8 $\pm 0.2b$	68.6 $\pm 0.5b$
	818.3 $\pm 0.2b$	402.7 $\pm 0.3b$	539.6 $\pm 0.4b$	63.7 $\pm 0.1b$
Pyloric in awassi hamadani	1112.3 $\pm 0.19b$	353.5 $\pm 1.6b$	775.4 $\pm 0.1b$	64.4 $\pm 0.2b$
	963.9 $\pm 0.23b$	313.7 $\pm 0.7b$	715.2 $\pm 0.3b$	58.2 $\pm 0.6b$

Most of the abomasum's fundic area is mobile and intraperitoneal. Protection, support for structure, and less friction against nearby organs are all provided by a thicker serosa. The serosa needs to be strong enough to sustain this weight and preserve organ shape because the fundic mucosa is extremely thick and gland-rich. Contributing to mesenteric connections, the serosa supplies the active metabolic mucosa with blood vessels, lymph nodes, and nerves (25,26).

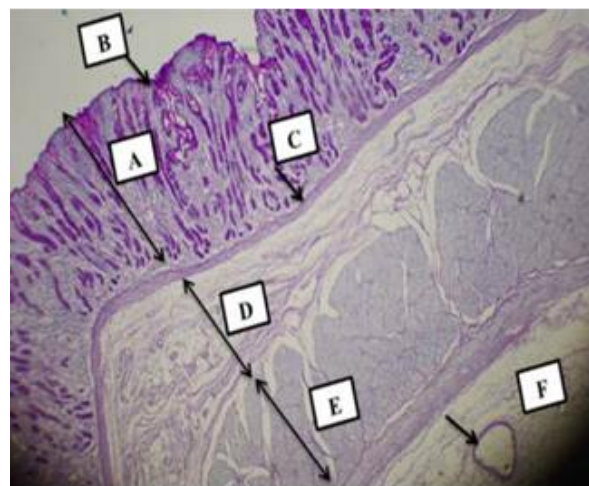
The glands occurred in a small fraction of branches, which are pyloric glands, and were bordered with epithelium resembling that of the fundus and heart. When lengthy pyloric glands developed, it was observed that their lumen was wider than that of fundus glands, that interacted well with the reagent (PAS). According to histochemical data, the stomach cell composition varied between research animals and between the abomasum's sections, and the fundic revealed a significant level of mucous secretion. With PAS and AB, the mucous cell mucin staining intensity is faint in the heart, moderate, and robust in the fundic and pyloric (Fig. 2,8). Physiological or functional variations pertaining to breed characteristics may exist: disparities in body size. Because Hamdani sheep are typically larger, their total rumen volume may be higher, but this is not a structural difference; rather, it is proportionate to body size. Capacity to intake feed Bigger animals may eat more forage only by virtue of their size rather than because their stomachs are different. There are more gastric pits in the fundic area (Histogram 1), Hydrochloric acid, pepsinogen, intrinsic variable, and mucus are all secreted by the fundic glands. To accommodate a high number of stomach glands, several, deep gastric pits have to be built. Because each gastric pit expands into multiple long, branching fundic glands, a high pit frequency increases the area of secretory surface (27,28). While enabling mucus against top epithelial cells to cover and shield the mucosa from acids and enzymes, gastric pits aid in directing secretions to the lumen. Since the fundic region contains the greatest amount of gastric glands and is the primary site of acids and enzymes secretion, it has the greatest number of gastric pits. A high cellular density is necessary for the digestion of protein from microbial and plant material coming from the forestomachs, which requires a great deal of acid and enzymes (29,30).



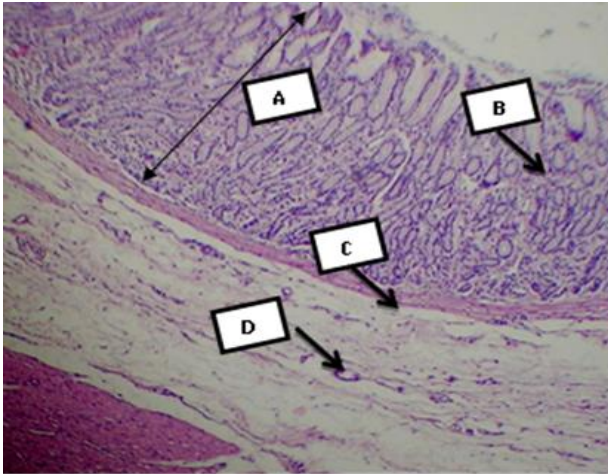
**histogram 1.** Measurements deep of pits of abomasum in Awassi and Hamdani Sheep,  $\mu\text{m}$



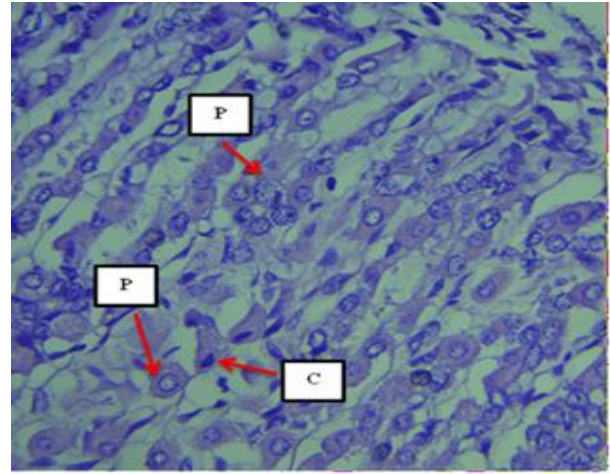
**Figure 1.** Longitudinal microscopic section of the cardiac region in hamadani, mucosa (A), submucosa (B), muscularis (C), PAS 40X



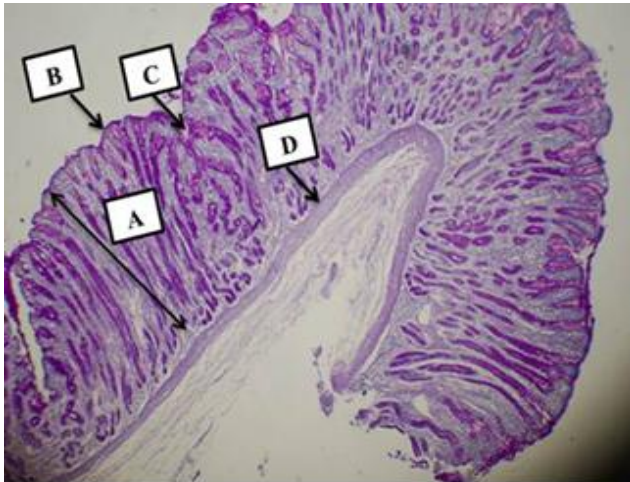
**Figure 2.** microscopic section of the pyloric region in awassi, mucosa (A), epithelium (B), muscularis mucosa (C), submucosa (D), muscularis externa (E), vein (F), PAS-AB 40X



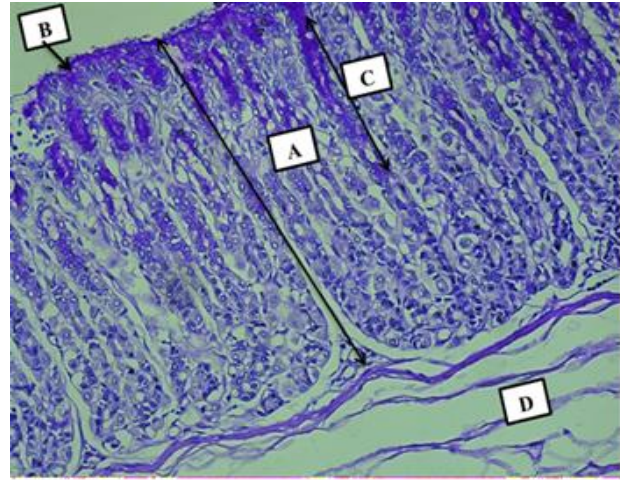
**Figure 3.** microscopic section of the fundic region in hamadani, mucosa (A), Pits (B), muscularis mucosa (C), blood vessels (D), H&E Stain 40X



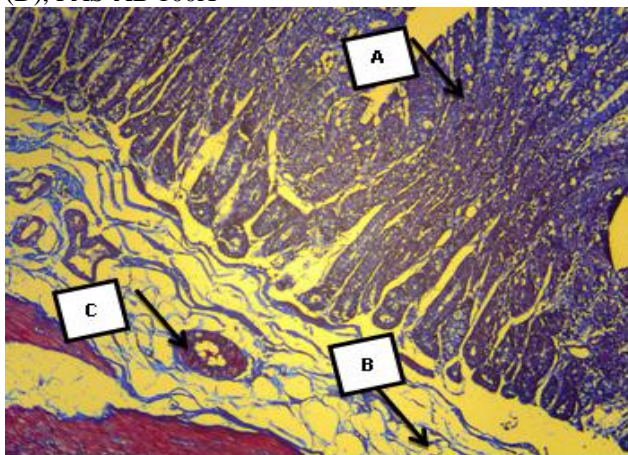
**Figure 6.** Longitudinal microscopic section of the pyloric region in awassi, parietal cell (P), chief cell (C), AB Stain 400X



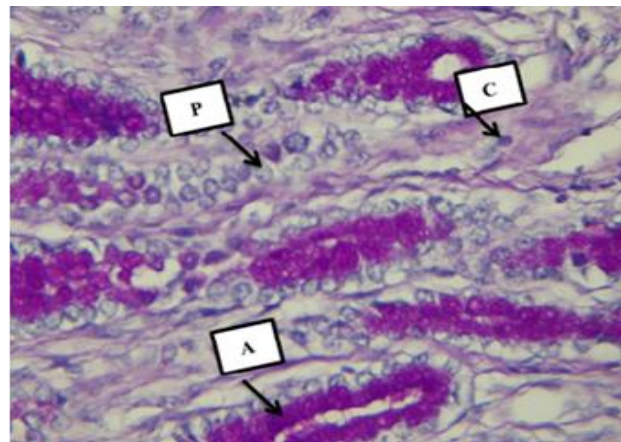
**Figure 4.** microscopic section of the fundic region in awassi, mucosa (A), epithelium (B), gastric pits (C), muscularis mucosa (D), PAS-AB 100X



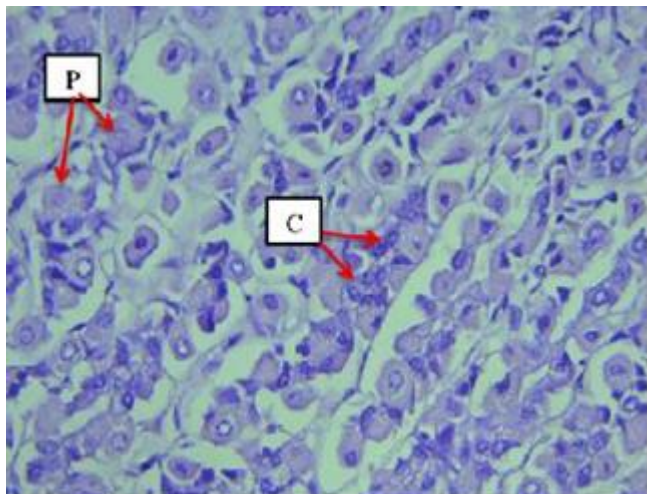
**Figure 7.** Longitudinal microscopic section of the mucosa in pyloric region in awassi, epithelium (A), lamina propria (B), Pits (C), muscularis mucosa (D), PAS Stain 200X



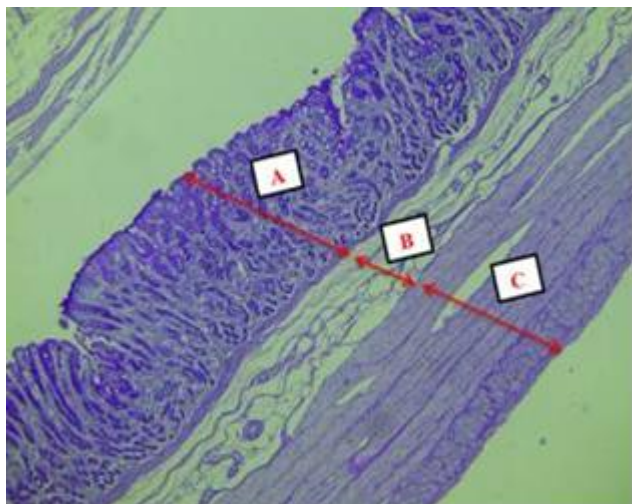
**Figure 5.** Longitudinal section of the mucosa in cardiac region in Hamdani sheep, gastric Pits are deep (A), collagen fiber (B), blood vessels (C), tunica muscularis(D), Masson Stain 100X



**Figure 8.** Cross microscopic section of the pyloric region in awassi, gastric pits with weak mucosa secretion (A), chief cell (C), parietal cell (P), PAS-AB 400X



**Figure 9.** Longitudinal section of the pyloric region in Hamdani sheep, gastric Pits are deep, parietal cell (P), chief cells (C), AB Stain 400X



**Figure 10.** Longitudinal microscopic section of the Pyloric region in Awassi sheep, mucosa (A), submucosa (B), muscularis externa is thickest (C), PAS 40X

### CONCLUSION

The various functions of cardiac, fundic, and pyloric areas of the abomasum in digesting are reflected in the disparities between their exterior and internal surfaces. The current study's results showed that different varieties of sheep had different stomach histology features, which aids in the ongoing effort to determine how closely related these animals are to one another. Greater body weights are frequently attained by Awassi sheep, which results in thicker tissue. This explains why Hamdani sheep bred in conventional ways have thinner abomasal layers. Hamdani and Awassi sheep differ mostly in abomasal histomorphometry because of Adaptive physiological reactions, metabolic and productivity demands, feeding schedule, and genetic background.

### Acknowledgements

We would like to express our gratitude to everyone who helped us complete and publish this research. Their efforts are much appreciated.

### Conflict of Interest

According to the writers of the manuscript, there were no such not conflicts of interest within the writing process.

### REFERENCES

- 1) Mosavat, N., & Chamani, M. (2013). A review: Comparison between grazing behavior of cattle and sheep. *Global Journal of Biodiversity Science and Management*, 3(2), 138-140.
- 2) Malik, S.A. (2014). Anatomical studies on the oesophagus and stomach of Gaddi sheep. M.V.Sc Thesis, Chaudhary Sarwan Kumar Himachal Pradesh Krishi Vishwavidyalaya, Palampur (H.P), India.
- 3) Kumari, P., Panchal, K.M., & Vyas, Y.L. (2013). Gross and biometrical studies on viscera of Black Buck (*Antelope cervicapra*). *Indian Journal of Veterinary Anatomy*, 25(2), 86-88.
- 4) Lakshmishree, K.T. (2014). Gross and Histomorphological studies on forestomach of wild ruminants in comparison with domestic ruminants. Retrieved from [krishikosh.egranth.ac.in](http://krishikosh.egranth.ac.in).
- 5) Machado, M.R.F., & Oliveira, F.S. (2008). Gross anatomy of the stomach of the Marsh deer. *Brazilian Journal of Morphological Sciences*, 25(1-4), 1-34.
- 6) Mahendrakumar, S.T. (2017). Gross, biometrical and histological studies on the ruminant stomach of the Surti goat (*Capra hircus*). M.V.Sc Thesis. Anand Agricultural University, Gujarat, India.
- 7) Nurliani, A., Budipitojo, T., & Kusindarta, D.L. (2015). Morphological characteristics of the stomach of swamp buffalo (*Bubalus bubalis*). *Aceh International Journal of Science and Technology*, 4(3), 78-82
- 8) Poonia, A., Kumar, P., & Kumar, P. (2013). Histological Studies on the Omasum of the Sheep (*Ovis Aries*). *Indian Journal of Veterinary Anatomy*, 24(2).
- 9) Rasheed, M. A., & Ibrahim, A. H. (2025). Ontogenetic Morphological And Histochemical Evaluation Of The Abomasum In Local Lambs And Goat Kids (1–4 Months Of Age): A Comparative Study. (2025). *The Review of Diabetic Studies*, 1-14.
- 10) AL-Baghdady, E. F; AL-Mehanna, N. H., & Kadhim, K. H. (2012). The Distribution of the Goblet cells, Paneth cells and Brunner's glands in Duodenum of Adult one Humped Camels. *Al- Qadisiyah Journal of Veterinary Medicine Sciences*, 11(2): 46-52.
- 11) Ganong, W. F. (2005). *Review of Medical Physiology*. 28th ed. Alange Medical Company London. Pp: 955-969.
- 12) Dyce, K. M., Sack, W. O., & Wensing, C. J. G. (2010). *Textbook Of Veterinary Anatomy-E-Book*. Elsevier Health Sciences; Pp:200-300.
- 13) Eurell JAC (2004). *Veterinary histology*, Teton New Media, U.S.A. 2004; 64-67 p.
- 14) Ibrahim, Z. H., & Almundarij, T. I. (2023). Morphology of the dromedary camel stomach with reference to

- physiological adaptation. *Slovenian Veterinary Research/Slovenski Veterinarski Zbornik*, 60.
- 15) Suvarna SK, Layton C, & Bancroft JD. (2018). *Bancroft's theory and practice of histological techniques*, 8<sup>th</sup> ed. Churchill Livingstone Elsevier Philadelphia.; 176 -725 p.
  - 16) Al-Rawi KM, & Kalaf-Allah IS. *Design and Analysis Agriculture Experiments*. Dar-Al Kutub-Mosul, Iraq.1980; 65, 95-107 p.
  - 17) Samuelson, DA (2007), *Textbook of veterinary histology*. 1st Edn., Philadelphia, W. B. Saunders Co; PP: 323-335.
  - 18) Solcia, E., Rindi, G., Buffa, R., Fiocca, R., & Capella, C. (2000), *Gastric endocrine cells: types, function and growth. Regulatory peptides*; 93(1-3), 31-35.
  - 19) Al-Abedi, A. F; Saeed, A. A., & Al-Huosyney, K. S. (2020). Study of  $\alpha$ - amylase and lipase enzymes of awassi sheep fed by levels of dietary protein and probiotic additives. *Journal of Kerbala for Agricultural Sciences*, 7(1): 1-9.
  - 20) Amit, P., & Pawan, K. (2017). Histoarchitecture and histochemical studies on the abomasum of sheep (*Ovis aries*). *Indian Journal of Veterinary Anatomy*, 29(1): 1-4.
  - 21) AL-Haaik, A. G. (2009). Study histological and morphological of the mucous membrane of the pylori area of domestic sheep and goats: *Iraqi Journal of Veterinary Sciences*,32(1):193-198.
  - 22) Tharwat, M., Al-Sobayil, F., Ali, A., & Buczinski, S. (2012). Transabdominal ultrasonographic appearance of the gastrointestinal viscera of healthy camels (*Camelus dromedaries*). *Research in veterinary science*; 93(2), 1015-1020.
  - 23) Trandaburu, T., & Trandaburu, I. (2009). The immunohistochemical localization of synaptophysin protein (p38) in the gastro-entero-pancreatic (GEP) system of reptiles. *Acta histochemica*, 111(6), 476-487.
  - 24) Vater, A. L., Zandt, E., & Maierl, J. (2021). The topographic and systematic anatomy of the alpaca stomach. *The Anatomical Record*; 304(9), 1999-2013.
  - 25) Wang, J. L., Lan, G., Wang, G. X., Li, H. Y., and Xie, Z. M. (2000), *Anatomical subdivisions of the stomach of the Bactrian camel (Camelus bactrianus)*. *Journal of Morphology*; 245(2), 161-167.
  - 26) Wang, J., Li, H., Zhang, L., Zhang, Y., Yue, M., Shao, B., & Wang, J. (2014), *Caracterización Histomorfométrica del Preestómago del Yak (Bos grunniens) en la Meseta Qinghai-Tíbet*. *International Journal of Morphology*, 32(3), 871-881.
  - 27) Worthington, J. J., Reimann, F., & Gribble, F. M. (2018), *Enteroendocrine cells-sensory sentinels of the intestinal environment and orchestrators of mucosal immunity*. *Mucosal immunology*; 11(1), 3-20.
  - 28) ALJubouri, T. R., AL-Khafaji, F. M., & AL-Shuhaib, M. B. S. (2025). comparative analysis of sheep growth traits in karakul, al-naimi, and hamdani breeds. *Assiut Veterinary Medical Journal*, 71(184), 264-279.
  - 29) Agrawal, A. R; Karim, S. A; Kumar, R; Sahoo, A., and John, P. (2014). *Sheep and goat production: basic differences, impact on climate and molecular tools for rumen microbiome study*. *International Journal of Current Microbiology and Applied Sciences*, 3(1): 684-706.
  - 30) Al-Neamy, E. M. K. A. (2007). *Anatomical, histological and ultrastructural study of Abomasum and its glands development in Iraqi male goat*, Ph D thesis Baghdad university Collage. *Veterinary Medicine*. Pp:100-120.